Cleft Surgery in Rural Bangladesh: Reflections and Experiences

Shahid R. Aziz, DMD, MD, Samuel T. Rhee, MD,† and Imre Redai, MD‡*

Purpose: The authors review their experiences during multiple cleft surgical missions to rural Bangladesh from 2006 to 2008. A significant number of patients who underwent primary palatoplasty or cheiloplasty were of adult age or size. Adult primary cleft lip and palate repair is often more challenging than repair at the standard age of fewer than 2 years. This patient population is rarely seen in the United States, but may be treated more often by American surgeons during surgical missions to the developing world. This report discusses the experiences of the authors' treatment of cleft lips and palates in rural Bangladesh.

Patients and Methods: One hundred forty-six cleft-lip and cleft-palate patients were treated during 3 missions to rural Bangladesh, from 2006 to 2008. Thirty-three (23%) patients were of adult size, and aged 13 to 35 years. One hundred thirteen (77%) patients were aged 12 years or younger. Unilateral cleft lips were repaired with a Millard advancement-rotation technique. Bilateral cleft lips were repaired via the 1-stage procedure advocated by Mulliken and Salyer. Cleft palates were repaired using a 2-finger flap method.

Results: Overall, 8 of 146 patients (5.5%) had nonlife-threatening complications (infection or wound dehiscence) requiring subsequent revision surgery. The adult-sized patients had clefts of significantly increased size secondary to patient growth, as well as maxillary expansion transversely and anteriorly. Adult cleft-lip repair required significant soft-tissue dissection to close the cleft adequately, and ensure symmetry to the upper lip and alar bases. However, this procedure sometimes resulted in placement of the lip cicatrix in an anatomically disadvantageous position. In addition, with the increased transverse dimension of the adult cleft palate, tension-free 3-layer closure was difficult. Again, aggressive dissection of the soft tissue was required: the nasal and muscular layers were closed without much tension, but oral closure was often under tension, requiring the assistance of dermal biomaterials to bolster the repair.

Conclusions: Patients in the developing world often have limited access to specialized health care, and may not realize that cleft lips and palates can be repaired. As a result, there is an increased incidence of unrepaired clefts in adult-sized individuals in this part of the globe. The American surgeon may encounter these patients during surgical missions. The surgeon should be prepared to repair adult patients with clefts that are significantly enlarged in all 3 dimensions. Closure will require significant soft-tissue dissection as well as the use of biomaterials as needed to repair wide cleft palates.

J Oral Maxillofac Surg 67:1581-1588, 2009

"Whenever a lip, in particular the uppermost one, is cleft by birth or nature, it is called a harelip, because in hares the uppermost lip is quasi-cleft too . . . It causes great ugliness of the face but also prevents newborn children from sucking correctly and afterwards from speaking clearly . . . and if the cleft is large, such people cannot help speaking nastily and unacceptably through their nose for the term of their life."

—Lorenz Heister, 18th Century German Anatomist and Surgeon[1]

Specialized health care in the developing world is often nonexistent for those who are extremely poor or living in rural areas. Bangladesh is no exception. In a country of 150 million, there are 15 plastic sur-

*Associate Professor, Department of Oral and Maxillofacial Surgery, UMDNJ-New Jersey Dental School, and Division of Plastic and Reconstructive Surgery, UMDNJ-New Jersey Medical School, Newark, NJ.

†Director, Craniofacial Surgery Program, and Assistant Professor, Division of Plastic Surgery, Department of Surgery, Weill Cornell Medical College, New York Presbyterian Hospital, New York, NY.

‡Assistant Professor, Department of Anesthesiology, Columbia University College of Physicians and Surgeons, New York, NY.

Address correspondence and reprint requests to Dr Aziz: Department of Oral and Maxillofacial Surgery, UMDNJ-New Jersey Dental School, 110 Bergen Street, Room B854, Newark, NJ 07103; e-mail: azizsr@umdnj.edu

0278-2391/09/6708-0002$36.00/0

doi:10.1016/j.joms.2008.11.021

Table 1. CLEFT LIP AND PALATE PATIENTS TREATED DURING BANGLADESH MISSION OF 2006 TO 2008

Age	<1 Year Old	1 to 12 Years Old	≥13 Years Old
UCCL	10	45	13
UICL	0	23	13
BCCL	3	4	2
BICL	0	5	1
CP	2	21	4
Total	15	98	33

Abbreviations: UCCL, unilateral complete cleft lip; UICL, unilateral incomplete cleft lip; BCCL, bilateral complete cleft lip; BICL, bilateral incomplete cleft lip; CP, cleft palate.

Aziz, Rhee, and Redai. Cleft Surgery in Rural Bangladesh. J Oral Maxillofac Surg 2009.

geons.[2] In 2000, the International Association of Oral and Maxillofacial Surgeons (IAOMS) documented 1 trained oral and maxillofacial surgeon per 24 million people (6 in the nation).[3] The current IAOMS directory lists 14 members from Bangladesh, with 12 based in the capitol, Dhaka.[4] As a consequence, an estimated 300,000 Bengalis are suffering with unrepaired cleft lips and palates.[5]

Although numerous techniques and protocols can treat this congenital deformity, the surgical literature is consistent in recommending early repair, typically completing primary repair of the lip and palate by age 2 years. A commonly accepted protocol in many surgical textbooks is repair of a cleft lip at 10 to 12 weeks of age, followed by primary palatoplasty at 9 to 12 months of age, before the development of speech. Some centers delay palatal repair until after 2 years of age, to allow for maxillary skeletal growth, and to minimize the risks of anesthesia. As such, it is exceptionally rare for American surgeons to perform primary repair of a cleft lip or palate in adult-sized individuals (for the purposes of our review, this would be an individual aged 13 years or older, based on the anesthesia guidelines of the American Association of Oral and Maxillofacial Surgeons[6]). However, in developing nations with limited specialized health care, untreated cleft lips and palates in adults are found with increasing frequency. Medical personnel participating in international surgical missions, particularly to Africa and the Indian subcontinent, may encounter this unique category of cleft patient. Although sound knowledge of the fundamentals of cleft surgery will certainly allow any surgeon to repair an adult cleft lip or palate adequately, obtaining the most favorable surgical outcome may require creative modification to the design of the cleft surgery secondary to various factors, including the increased size of the adult cleft. We review the experiences and challenges of multiple cleft missions to rural Bangladesh.

Patients and Methods

From 2006 to 2008, the authors traveled annually to Bangladesh to surgically treat patients with either cleft lips or cleft palates. The 2006 mission included 3 days of surgery. The 2007 and 2008 missions each included 6 days of surgery. The surgical teams consisted of 3 anesthesiologists, 2 attending surgeons (except in 2007, when there were 3 surgeons), 2 nurses, and 1 or 2 surgical residents.

In total, 146 cleft-lip and cleft-palate patients were treated: 129 cases by the authors, and an additional 17 cases by a third attending surgeon who participated in the 2007 mission (Table 1). One hundred thirteen patients (77%) were aged 12 years or younger: 90 underwent primary cheiloplasty, and 23 underwent cleft-palate repair. Thirty-three patients (23%) were of adult height and weight. These patients ranged in age from 13 to 35 years. Twenty-nine of these patients had an untreated cleft lip, and underwent primary cleft-lip repair. The remaining 4 patients had a cleft palate only, and underwent primary palatoplasties.

All procedures were completed under the auspices of Impact Foundation Bangladesh, a nonprofit, nongovernmental health care foundation based in Dhaka, Bangladesh. Seventy-one surgical procedures were completed on Impact's hospital ship, the "Jibon Tari" (Bengali for "Boat of Life") (Fig 1). The remaining 75 surgeries were completed on land at Impact's Masudul Haque Memorial Community Health Centre in Chuadanga, Bangladesh. The foundation's local physicians prescreened all potential patients for surgery. Recruitment occurred via newspaper, word of mouth, or local fieldworkers traveling to surrounding villages to identify potential patients. Initial inclusion criteria included any unrepaired cleft lip or cleft palate. At the start of each mission, before surgery, patients were evaluated by the team's attending anesthesiologists and surgeons. Perioperative risks were

FIGURE 1. Impact Foundation Bangladesh's floating hospital ship, the "Jibon Tari."

Aziz, Rhee, and Redai. Cleft Surgery in Rural Bangladesh. J Oral Maxillofac Surg 2009.

assessed based on physical examination, weight (minimum of 10 pounds), and a complete blood count (minimum hemoglobin of 10 g/dl). Only patients who were good candidates for general anesthesia and could obtain an appropriate surgical result were scheduled for surgery.

Anesthetic Technique

All patients underwent general endotracheal anesthesia with locally injected lidocaine or bupivicaine solutions. Dehydration is a concern in a hot climate, and patients were encouraged to take clear liquids up to 2 hours before surgery. Even with this precaution, several children needed intravenous hydration preoperatively. All patients were given a wrist bracelet for identification purposes.

Anesthesia machines in Bangladesh were simple and reliable (Soft Lander, Sin-ei Industry Co, Ltd, Saitama, Japan), and were connected to a circle, Jackson-Reese, or Bain circuit as needed. Intraoperative monitoring complied with American Society of Anesthesiologists standards, except for a lack of airway pressure measurements.

Children underwent inhalational induction. Adults received an intravenous induction of anesthesia. Anesthesia was maintained using halothane, nitrous oxide, and oxygen. Halothane is a common inhalation agent in the developing world because it is inexpensive, but it may cause arrhythmias after an exogenous administration of catecholamines.[7] As such, local anesthesia with epinephrine was kept to a minimum. Muscle relaxants were used sparingly, and in small doses (rocuronium, 0.3 mg/kg). This allowed for spontaneous ventilation throughout procedures, and avoided any reversal of neuromuscular blockade, insofar as the administration of parasympatholytic agents is undesirable in children in hot climates. Patients received a slow bolus of dexmedetomidine (0.5 μg/kg) that reduced the anesthetic and postoperative analgesic requirements. Preoperative antibiotics were administered intravenously just before surgery. Postoperative analgesia was provided, using acetaminophen, ketorolac, and morphine when available. Ringer's lactate was used as maintenance fluid, and was continued postoperatively until oral intake was reestablished.

Preformed, age-appropriate Ring-Adair-Elwyn (RAE) endotracheal tubes were used for endotracheal intubation. Two problems were encountered. Firstly, parents were often uncertain about the age of their children; in these cases, we used the little finger as a gauge to select the appropriate endotracheal tube. Secondly, children in rural Bangladesh were smaller and shorter than their English counterparts, who had served as templates for the developers of the RAE tube. This resulted in the RAE tube's tip sliding into the right mainstem bronchus on a regular basis. Early recognition of this is important for intraoperative oxygenation, and to prevent postoperative atelectasis. Careful auscultation after endotracheal intubation and surgical positioning was used to confirm the proper location of an endotracheal tube before surgical draping. If needed, a small cushion was shaped from gauze and used as padding between the chin and the curve of the RAE tube. Throat packs were used for most cases, and the anesthesiologist was responsible for keeping track of the packs. All patients recovered at a location adjacent to the operating rooms. Postoperative atelectasis was the main concern, and all patients received aggressive, early chest physiotherapy.

Lip and Palate Repair

Four types of unrepaired cleft lips were surgically treated:

1. Unilateral complete cleft lip;
2. Unilateral incomplete cleft lip;
3. Bilateral incomplete cleft lip; and
4. Bilateral complete cleft lip.

Unilateral complete cleft lips were repaired using classic Millard rotation-advancement flaps. In cases where an incomplete unilateral cleft lip had minimal soft-tissue bridging (such as a Simonart's band), the atretic soft tissue was completely excised, and the cleft lip was subsequently repaired with a rotation-advancement technique.[8]

In cases where the incomplete cleft lip had a significant amount of soft tissue present, the cleft was repaired with either a Randall-Tennison triangle flap technique or a modified straight-line repair. Bilateral cleft lips were repaired according to the 1-stage procedure of Mulliken[9] and Salyer.[10] All cleft palates were noted to be complete in nature. All patients underwent the 2-finger flap palatoplasty advocated by Bardach.[11] All incisions were closed with resorbable suture.

Postoperatively, all patients were hospitalized between 2 and 7 days. Patients received oral antibiotics, a soft diet, and intravenous fluid hydration. Patients and families were given a 5-day supply of oral antibiotics upon discharge, specific local wound-care instructions, and strict follow-up appointments with the Impact Foundation Bangladesh medical personnel no later than 10 days after discharge.

After the 2006 mission, 1 pediatric patient developed mild infection of a lip repair, resulting in a wound dehiscence at the right alar base. Secondary revision of the alar base was performed after the infection had resolved. During the 2007 mission, 6

Table 2. COMPLICATIONS IN 8 OF 146 (5.5%) PATIENTS

Patient Type	2006	2007	2008	Totals
Cleft lip	1	4	0	5
Cleft palate	0	2	1	3
Totals	1	6	1	8

NOTE. All patients were pediatric, ie, under 13 years of age.

Aziz, Rhee, and Redai. Cleft Surgery in Rural Bangladesh. J Oral Maxillofac Surg 2009.

pediatric patients (4 patients after cleft-lip repair, and 2 patients after palatoplasty) developed postoperative infections with associated wound dehiscences. All 6 patients' infections resolved with oral antibiotics and local wound care. All patients subsequently underwent successful secondary repair. During the 2008 mission, 1 pediatric patient developed partial necrosis of the distal portion of the right palatal flap, with development of a small palatal fistula (Table 2).

Cleft Surgical Missions in Rural Bangladesh

Few 60-minute surgical procedures have as profound an impact on a person's life as a cleft-lip repair. In the developing world, where specialized surgical care is often the exception rather than the norm, millions of children and young adults suffer with unrepaired clefts. In Bangladesh, a nation of 150 million people, it is estimated that 300,000 people have untreated clefts; the majority are impoverished, and from rural areas. Rehabilitation of the cleft patient is also multidisciplinary. Genetic counseling, dental specialty care, speech pathology, audiology, and pediatrics are all among the typical cleft center specialties, in addition to surgery. Bangladesh lacks the resources to provide this comprehensive multispecialty care. This means that even those who are able to receive surgical care often lack the necessary supportive care. As a result, cleft patients in Bangladesh are often socially, intellectually, and cognitively impaired despite their surgical success, and are not productive members of Bengali society.[5] Local education in poor or rural areas also needs to be developed. Many patients were unaware that clefts can be surgically corrected, until a field health worker visited the patient's village. Moreover, many Bengalis do not realize that cleft lips and palates are a congenital anomaly of multifactorial etiology. A popular misconception holds that children with clefts are born to mothers who cut fish and vegetables on the night of a full moon while pregnant. As a result, many mothers feel responsible for their child's ailment, and often both mother and child are alienated by their family.[5]

The cleft problem in the developing world is further compounded by a lack of qualified surgeons to perform the work. In Bangladesh, this lack is being addressed on multiple levels. The most important initiative is the introduction of surgical training programs within Bangladesh. In 1990, a joint Australian-Bangladesh effort led to the development of the only oral and maxillofacial training program in the country, at Bangabandhu Sheikh Mujib Medical University, in Dhaka. This program was initiated by Dr Barry Fitzpatrick, an Australian maxillofacial surgeon, and Professor Motiur Molla, and accepts 4 to 5 surgeons per year in a 5-year training program[3] (Fig 2). In 2000, Dhaka Medical College Hospital initiated a postgraduate program in plastic surgery. Ten of the 15 plastic surgeons in-country were trained in this program.[2] With this increase in local surgical specialist care, mobile cleft camps have been developed, in which city-based surgeons travel to rural parts of Bangladesh and treat patients with clefts. Most of these camps have minimal surgical facilities, and are often limited to surgery under local anesthesia. As such, only lips are treated.[5]

International surgical volunteerism and teaching comprise a third way to increase cleft care in the developing world. Many organizations in the United States, such as Healing the Children Northeast (New Milford, CT; the American sponsor of the authors' missions to Bangladesh), will facilitate overseas travel of medical professionals to underserved areas. There are a number of remarkable opportunities to partici-

FIGURE 2. From left: S.T.R., Ms Christina Rozario (Impact Foundation Bangladesh), Dr Amy Tanchyk (oral and maxillofacial surgery resident, UMDNJ), S.R.A., Dr Motiur Molla (Professor and Chairman, Department of Oral and Maxillofacial Surgery, Bangabandhu Sheikh Mujib Medical University, Dhaka, Bangladesh), June 2007.

Aziz, Rhee, and Redai. Cleft Surgery in Rural Bangladesh. J Oral Maxillofac Surg 2009.

pate in or develop cleft-surgery teams in regions worldwide. The authors have participated in a total of 12 volunteer cleft programs, including five developed and led by S.R.A. Based on this experience, some basic guidelines are suggested to facilitate participation in cleft missions to the developing world:

1. For the novice mission participant, travel with an experienced team as an observer or assistant, to learn "the ropes" of medical missions, is advisable. After becoming comfortable with the logistics of cleft missions, the surgeon, on subsequent trips, should focus on surgical care. Of note, surgeons should be prepared to bring their own equipment and supplies (including surgical equipment, sutures, and headlights).
2. These missions are not intended to provide "practice" for the surgeon or surgical resident. Only individuals qualified to repair clefts in their home countries should be the primary surgeons on these missions to ensure the highest quality of repair, especially because operative conditions and surgical repairs are often more difficult on missions abroad. The goal of including surgical residents on missions is to expose them to surgical philanthropy and international volunteerism.
3. Team anesthesiologists must be experienced with both pediatric and adult anesthesia, and they should be comfortable working in less than ideal facilities. In addition, the mission team should bring multiple sets of portable anesthesia-monitoring equipment to augment and back up the host facility's anesthesia equipment.
4. Working with a credible local sponsoring organization or foundation is important. This often requires a scout visit to the organization by team leaders before the actual mission to evaluate facilities, organization personnel, and medical support. Local sponsors must be able to recruit and screen appropriate patients, provide facilities adequate to ensure patient safety, and have sufficient medical personnel to care for patients after the team has left the host country, to continue postoperative patient management.
5. Before surgery, each patient must be thoroughly evaluated by anesthesiologists to determine perioperative risks. This includes a proper physical examination and appropriate preoperative testing. In addition, surgeons must thoroughly evaluate a patient to ensure that the surgical anatomy is amenable to an adequate repair. No surgery should be performed in which an acceptable outcome is in doubt: "in dubio abstine" (when in doubt, abstain).
6. Create a surgical schedule in coordination with the host organization. Ensure that the schedule is not too overwhelming for the mission team as well as the host personnel. Operating while exhausted is a method likely to obtain a suboptimal surgical repair.
7. Arrange to work with local surgical personnel. Training local surgeons, anesthesiologists, and nurses in cleft surgery and patient management is as important as repairing the cleft itself. Training local personnel empowers these individuals to provide competent care on a local level to those in need, and is an investment in the evolution of adequate cleft management in the developing world (Fig 3).
8. Develop a small team of surgeons, anesthesiologists, and nurses who work well together. Team solidarity is key to a successful and rewarding mission experience. Personal conflicts within the team can be exacerbated because of the remote locations, resulting in attention diverted from medical care.
9. Postoperative care is important. Treatment should be identical to that in the United States. Intravenous antibiotics and fluids, local wound care, oral antibiotics, and analgesia are all part of the postoperative management of these patients. Consider keeping postoperative patients longer than is normally the case in the United States, if there are concerns about wound care, antibiotic administration, or nutrition after the patient is discharged.

Cleft lips and cleft palates are congenital anomalies that have been documented in the medical literature

FIGURE 3. S.T.R. and S.R.A. with Bangabandhu Sheikh Mujib Medical University oral and maxillofacial surgery residents Drs Jayanta and Haider, January 2008.

Aziz, Rhee, and Redai. Cleft Surgery in Rural Bangladesh. J Oral Maxillofac Surg 2009.

since the 4th century AD.[12] Typical surgical protocols include performing cleft-lip repair at ages 10 to 12 weeks, and primary palatoplasty at ages 9 to 12 months. The early timing of repair was shown to be advantageous in repairing cleft lips from an esthetic standpoint, because the cleft is less wide at this point. Many American centers advocate repair of cleft palates by age 1 year to facilitate feeding, and to maximize the development of appropriate speech patterns, although some centers prefer to delay closure until after 2 years of age. Early repair of cleft lips and cleft palates has disadvantages, most notably the resultant restriction of maxillary and midfacial growth.

Multiple studies compared unrepaired adult cleft-lip and cleft-palate maxillary morphology to that in adults with repaired clefts.[13-18] The results are well-documented: adults with unrepaired cleft lips or palates have maxillas with a normal to slightly prognathic cephalometric position anterior-posteriorly, and a normal to widened maxillary transverse width. Based on these studies, it is evident that the facial characteristics of an unrepaired adult cleft lip and palate patient are unique: a normal to slightly protrusive upper jaw, protruded maxillary anterior dentition, and a normal or slightly hypoplastic mandibular relationship. In addition, the cleft-lip and cleft-palate dimensions are that much greater, because the cleft grows proportionately with the surrounding anatomy.

The authors had a unique opportunity to complete primary palatoplasty and cheiloplasty on adult-sized cleft patients. Based on this experience, the following observations were noted. What is initially most striking about repairing an adult cleft lip is that the anatomic landmarks are appreciably easier to discern than in an infant. In addition, there is increased soft-tissue bulk that can be readily utilized during adult repair, but that is not present for repairs in an infant. However, the dimensions of the adult cleft gap can be appreciably larger. As such, aggressive soft-tissue dissection may be required as the rotation-advancement flaps are raised.

When repairing an adult cleft lip (particularly a unilateral complete cleft lip), the authors found it advantageous to rework some traditional conventions of lip repair to achieve improved final results. In exceptionally wide unilateral complete cleft lips, an adequate rotation/advancement of skin flaps was frequently best achieved by increasing the dimensions of the backcut, allowing for mobilization of the "C" flap across the cleft. In addition, alar-base dissection on the cleft side was often beneficial, as was more extensive dissection of the musculature. Such variations allowed for improved tension-free closure of the unilateral cleft lip and good symmetry in the alar-base reconstruction, but sacrificed esthetic scar placement to an extent (Fig 4). Postoperatively, secondary to aggressive muscle dissection, many complete cleft-lip

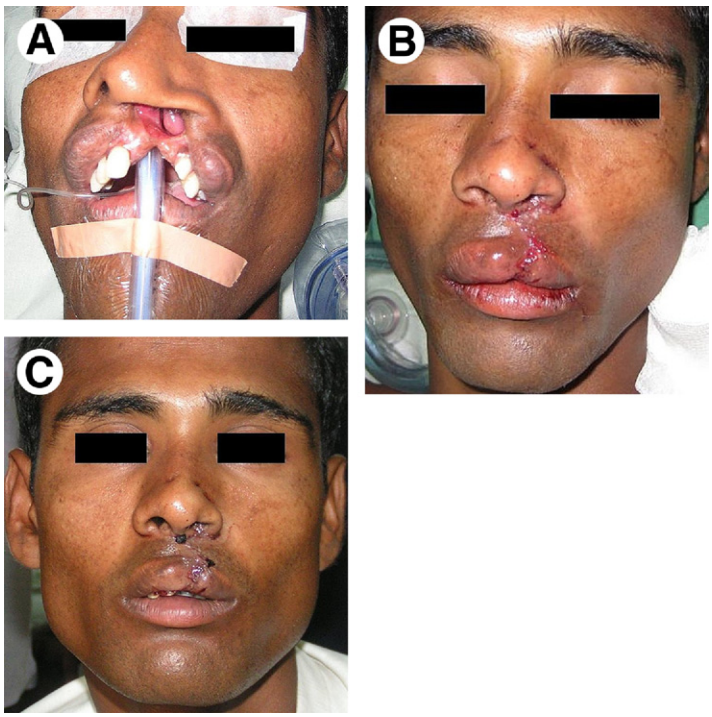

FIGURE 4. *A*, A 28-year-old male with large left unilateral complete cleft lip. *B*, Immediately after repair using Millard technique. Note the symmetry of alar bases, vermilion, and Cupid's bow; however, the incision design is not ideally placed. *C*, Four days after surgery.

Aziz, Rhee, and Redai. Cleft Surgery in Rural Bangladesh. J Oral Maxillofac Surg 2009.

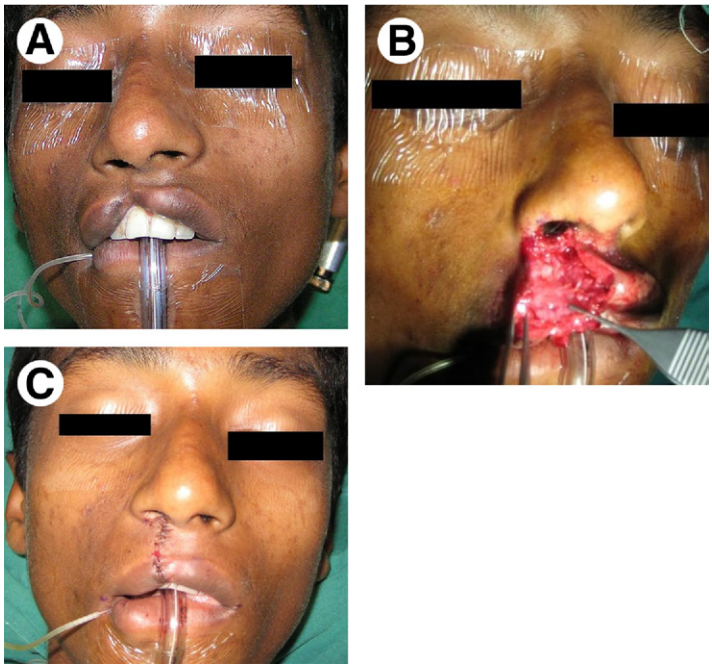

FIGURE 5. *A*, Seventeen-year-old male with right incomplete cleft lip. *B*, Aggressive muscle dissection. *C*, Final closure.

Aziz, Rhee, and Redai. Cleft Surgery in Rural Bangladesh. J Oral Maxillofac Surg 2009.

repairs had significant edema that lasted up to 3 weeks. For incomplete unilateral cleft lips, a simple straight-line closure or triangle flap was often adequate. Again, the anatomic landmarks were easily identified (Fig 5). Maxillary anterior teeth may interfere with the closure of the lip. These teeth are often protruded and rotated. This may create tension and a tenting effect on the lip repair. Although it is preferable to save the tooth if possible, if a tooth compromises adequate repair of the lip or is diseased (either carious or nonrestorable), it should be extracted (Fig 6). The average Bengali girl is married by age 14, so prioritizing teenage girls with cleft lips is important to improve their chances for matrimony.[19]

Primary palatoplasty in the adult is a significant challenge, secondary to the increased width of the cleft palate that is to be closed. Complete cleft palates with an associated alveolar cleft were repaired using the Bardach 2-finger flap technique. Isolated complete cleft palates were closed using a V-Y pushback technique. The primary problems with palatal closure in the adult cleft stemmed from increased cleft width, with vertically displaced palatal segments. This situa-

FIGURE 6. Maxillary dentition erupting into cleft.

Aziz, Rhee, and Redai. Cleft Surgery in Rural Bangladesh. J Oral Maxillofac Surg 2009.

FIGURE 7. Team from 2007 mission, surrounded by children from a village in Surajgonj District, Bangladesh (photograph courtesy of Bruce Byers).

Aziz, Rhee, and Redai. Cleft Surgery in Rural Bangladesh. J Oral Maxillofac Surg 2009.

tion is thought to be secondary to prolonged tongue interposition in the cleft.[20] In addition, adult cleft palates have increased mucoperiosteal fibrosis, making dissection of the palatal flaps difficult. The levator palatini muscle may have increased contracture in the adult cleft palate, resulting in a more difficult dissection and anatomic repositioning of this muscle. Finally, greater bleeding is often evident in adult palatal dissection, secondary to the increased tissue dissection of this surgery. With the increased size of a palatal cleft, the ideal 3-layer, tension-free closure can be challenging. Although the nasal mucosa and muscle layers were often closed with minimal tension, oral mucosal closures tended to have increased tension. To overcome this, outfracturing of the hamulus as well as careful dissection of the greater palatine neurovascular bundle from its foramen can be performed, to mobilize the palatal finger flaps further. In addition, the use of biomaterials as an adjunct may occasionally be helpful. Processed, acellularized, dermal biomaterials such as Alloderm (Life Cell Corp, Branchburg, NJ) or Dermamatrix (Synthes Maxillofacial, Paoli, PA) were used judiciously as onlay patches to support areas of increased tension. The processed dermal tissue was sutured on top of the area of tension, providing further support to the repair. It should be noted that whereas adult primary palatoplasty does not improve speech, it does significantly reduce nasal regurgitation and enhances oronasal hygiene.

Cleft missions to the developing world are an important and rewarding way for the American oral and maxillofacial surgeon to serve the global community. Because of limited access to specialized surgical care, American surgeons may find themselves faced with treating an adult with an unrepaired cleft lip or palate. Primary repairs of adult cleft lips and palates can be challenging, even for experienced cleft surgeons. The increased dimensions of the cleft may necessitate extensive soft-tissue dissection. The unrepaired cleft lip causes the developing maxilla to take a somewhat prognathic position relative to the mandible, with proclined anterior maxillary teeth. These teeth can create excessive tension on the lip repair, and may require extraction. The primary cleft palate in the adult is typically wide and fibrotic, making surgical closure more complex. Because speech development has already occurred in the adult, primary palatoplasty will not improve speech. However, the repair will minimize oronasal regurgitation. These international missions can be among the most rewarding experiences in a surgeon's career. Mission success can be optimized if surgeons travel with experienced teams that work well together and maintain appropriate safety, surgical, and medical-care standards. Sponsorship with appropriate host organizations and careful surgical case selection will also reduce the risk of potential complications. Training local surgeons in repair techniques empowers these individuals to continue the care of cleft patients in the future (Fig 7).

Acknowledgments

The authors thank the Impact Foundation Bangladesh and Healing the Children Northeast for their sponsorship, the Smile Train for financial support, and KLS Martin, Synthes Maxillofacial, and Stryker CMF for their instrumentation support of these missions to Bangladesh. Special thanks go to Dr Vincent Ziccardi for reviewing the manuscript.

References

1. Heister L: A General System of Surgery. London, W. Innys, 1757
2. Interplast: Dhaka, Bangladesh 2007. Available at: http://interplast.blogs.com/dhaka_bangladesh_2007. Accessed January 9, 2009
3. International Association of Oral and Maxillofacial Surgeons: History of IAOMS: 1992-2001. Available at: http://www.iaoms.org/History_1992_2001.aspx. Accessed January 9, 2009
4. International Association of Oral and Maxillofacial Surgeons: Available at: http://www.iaoms.org/IAOMSDIRECT/images/membership/membership_top.jpg. Accessed January 9, 2009
5. Ghani S, Mannan A, Sen S, et al: The problems of establishing modern cleft lip and palate services in Bangladesh. J Surg 2:43, 2004
6. Commission on Dental Accreditation: Accreditation Standards for Advanced Specialty Education Programs in Oral and Maxillofacial Surgery. Chicago, IL, American Dental Association, 2008, p 26
7. Pham AM, Tollefson T: Cleft deformities in Zimbabwe, Africa. Arch Facial Plast Surg 9:385, 2007
8. Salyer KE, Marchac A, Cheng MS, et al: Unilateral cleft lip/nose repair, *in* Losee JE, Kirschner RE (eds): Comprehensive Cleft Care. New York, McGraw Hill, 2009, pp 299-330
9. Mulliken JB: Principles and techniques of bilateral complete cleft lip repair. Plast Reconstr Surg 75:477, 1985
10. Salyer K. Primary bilateral cleft lip/nose repair, *in* Bardach J, Salyer K (eds): Salyer and Bardach's Atlas of Craniofacial and Cleft Surgery. Volume 2. Philadelphia, PA, Lippincott, 1999, pp 543-607
11. Bardach J: Two flap palatoplasty: Bardach's technique. Operative Techn Plast Reconstr Surg 2:211, 1995
12. Bill J, Proff P, Bayerlein T, et al: Treatment of patients with cleft lip, alveolus, and palate—A short outline of history and current interdisciplinary treatment approaches. J Craniomaxillofac Surg 34:17, 2006 (suppl 2)
13. Will L: Growth and development in patients with untreated clefts. Cleft Palate Craniofac J 37:523, 2000
14. Yang L: Effects of lip repair on maxillary growth and facial soft tissue development in patients with a complete unilateral cleft of lip, alveolus, and palate. J Craniomaxillofac Surg 34:355, 2006
15. Mars M, Houston W: A preliminary study of facial growth and morphology in unoperated male unilateral cleft lip and palate subjects over 13 years of age. Cleft Palate J 27:7, 1990
16. Capelozza L, Taniguichi SM, DaSilva O: Craniofacial morphology of adult unoperated complete unilateral cleft lip and palate patients. Cleft Palate Craniofac J 30:376, 1993
17. Bishar SE: Facial and dental relationships in individuals with cleft lip and/or palate. Oral Maxillofac Surg Clin North Am 14:411, 2002
18. Shetye P: Facial growth of adults with unoperated clefts. Clin Plast Surg 31:361, 2004
19. Paul AC, Spauwen P, Spronk CA, et al: Cleft lip and palate treatment in Bangladesh. Eur J Plast Surg 29:267, 2007
20. Ward C, James I: Surgery of 346 patients with unoperated cleft lip and palate in Sri Lanka. Cleft Palate J 27:11, 1990